

# FibriCheck's post-PVI solution

## An interesting use case



### Patient profile

- Age: 74
- Gender: Male
- Condition: AF
- Procedure: PVI Ablation

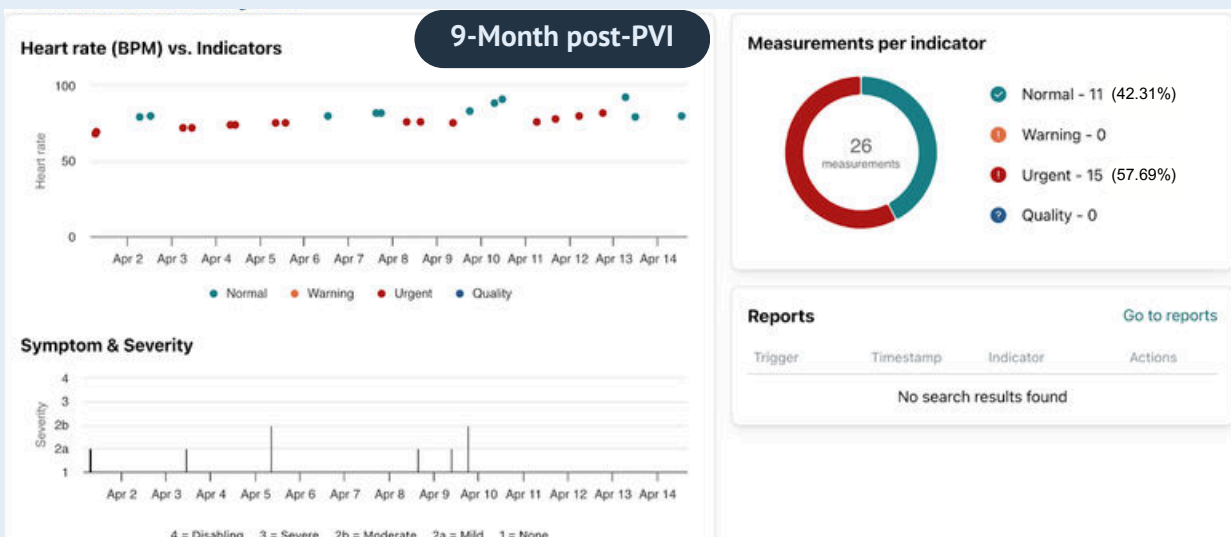
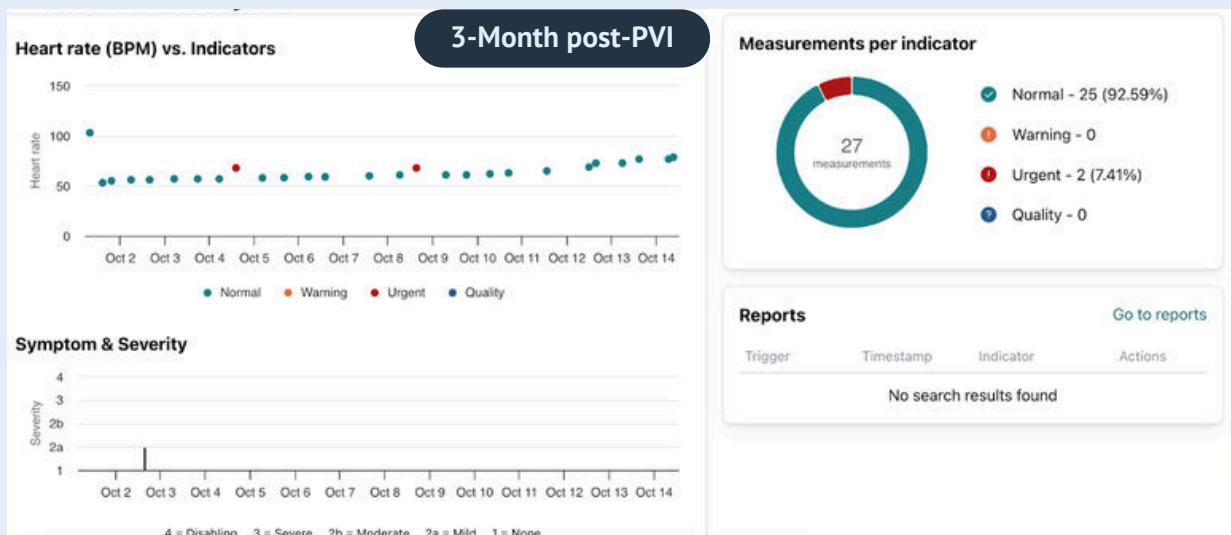
## Follow-up consultations

### 3-Month post-PVI follow-up

At the 3-month follow-up appointment post-ablation, the patient exhibited a low AF load of 7% and reported living symptom-free. The continuation of anticoagulation therapy was recommended due to an increased stroke risk. No further interventions were deemed necessary at this stage.

### 9-Month post-PVI follow-up

During the 9-month follow-up, the patient reported a recurrence of symptoms, with severity comparable to the pre-ablation period. An increase in AF load was noted, alongside a significant correlation between the symptoms and the rhythm disturbances.



### Management Decision

Given the initial positive response to the PVI ablation and the current high symptom-rhythm correlation, a redo ablation was planned for the patient.